



MORPHOMETRIC TOMOGRAPHIC ANALYSIS OF THE HEAD OF THE TRIDACTYL HUMANOID SPECIMEN FROM NASCA-PERU

Edgar Hernández-Huaripaucar¹
Bladimir Becerra-Canales²
Roger Zúñiga-Avilés³
Jorge Ybaseta-Medina⁴
Carlos Suarez-Canlla⁵
Hugo Caballero-Cornejo⁶
Irvin Zúñiga-Almora⁷

ABSTRACT

Objective: To report the tomographic and morphometric analysis of the head of the tridactyl humanoid specimen from Nazca, Peru.

Method: A qualitative case study approach. RadiAnt DICOM Viewer software version 4.2.1 was used to analyze lengths, diameters, and volume in tomographic images of the head. The morphological biometric analysis applied anthropometric methods using some craniometric points and cephalometric angles.

Results and Discussion: As a result, it is reported that there are atypical, strange, and exceptional morphometric imaging features in the cephalic segment of specimen M01. The cephalometric analysis based on the ANB angle revealed a class II skeletal pattern, and according to the Bjorl-Jarabak analysis, it has a convex facial profile with hypodivergent growth (brachyfacial). The patient also has maxillary biprotrusion, severe protrusion of upper and lower incisors, loss of teeth, presence of root remnants, severe dental abrasion, non-assessable canine class, absence of three third molars and ocular protrusion. Based on craniometric points, the SNA angle (Sella, Nasion and Point A) and the SNB angle (Sella, Nasion and Point B) maxillary protrusion and mandibular protrusion were diagnosed.

Implications of the research: It is concluded that the combination of uncommon morpho-anatomical features in the maxillofacial and cranial massif do not correspond to a human craniofacial biotype, but could be considered as suggestive findings of morpho-anatomical features typical of a hominid species similar to humans.

Originality/Value: The expansion of biometric and morphoanatomical data of the head reinforces the hypothesis that morphologically it would be a non-human hybrid species.

Keywords: Imaging, Cephalometry, Tridactyl, Bioarchaeology, Postmortem Case Report.

¹ Universidad Nacional San Luis Gonzaga (UNSLG). Provincia de Ica, Departamento de Ica, Perú.

E-mail: edgar.hernandez@unica.edu.pe Orcid: <https://orcid.org/0000-0002-1677-0670>

² Universidad Nacional San Luis Gonzaga (UNSLG). Provincia de Ica, Departamento de Ica, Perú.

E-mail: bladimir.becerra@unica.edu.pe Orcid: <https://orcid.org/0000-0002-2234-2189>

³ Universidad Nacional San Luis Gonzaga (UNSLG). Provincia de Ica, Departamento de Ica, Perú.

E-mail: rogerzua1618@gmail.com Orcid: <https://orcid.org/0000-0001-5641-0787>

⁴ Universidad Nacional San Luis Gonzaga. Ica, Perú.

E-mail: jybaseta@unica.edu.pe Orcid: <https://orcid.org/0000-0003-1224-1357>

⁵ Universidad Nacional Mayor de San Marcos (UNMSM). Lima, Perú.

E-mail: csuarezc@unmsm.edu.pe Orcid: <https://orcid.org/0000-0003-4719-1409>

⁶ Universidad Nacional Mayor de San Marcos (UNMSM). Lima, Perú.

E-mail: hcaballeroc@unmsm.edu.pe Orcid: <https://orcid.org/0000-0002-7901-8523>

⁷ Servicios en Tecnologías Educación e Innovación SAC. España.

E-mail: zai.zalud@gmail.com Orcid: <https://orcid.org/0009-0009-2770-4466>



ANÁLISE MORFOMÉTRICA TOMOGRÁFICA DA CABEÇA DO ESPÉCIME HUMANÓIDE TRIDÁCTILO DE NASCA-PERU

RESUMO

Objetivo: Comunicar a análise tomográfica e morfométrica da cabeça do espécime humanoide tridáctilo de Nasca-Peru.

Método: Pesquisa de abordagem qualitativa do tipo estudo de caso. O software RadiAnt DICOM Viewer versão 4.2.1 foi aplicado para analisar comprimentos, diâmetros e volumes em imagens tomográficas da cabeça. A análise biométrica morfológica aplicou métodos antropométricos utilizando alguns pontos craneométricos e ângulos cefalométricos.

Resultados e Discussão: Como resultados, relata-se que existem características de imagem morfométrica atípicas, estranhas e excepcionais no segmento cefálico do espécime M01. A análise cefalométrica baseada no ângulo ANB revelou padrão esquelético classe II e segundo análise de Bjorl-Jarabak apresenta perfil facial convexo com crescimento hipodivergente (Braquifacial). Apresenta também biprotrusão maxilar, protrusão severa de incisivos superiores e inferiores, perda de dentes, presença de remanescentes radiculares, abrasão dentária grave, classe canina não avaliável, ausência de três terceiros molares e protrusão ocular. Com base nos pontos craneométricos, foram diagnosticados o ângulo SNA (Sella, Nasion e Ponto A) e o ângulo SNB (Sella, Nasion e Ponto B) protrusão maxilar e protrusão mandibular.

Implicações da pesquisa: Conclui-se que a conjugação de características morfoanatômicas incomuns no maciço maxilofacial e craniano não corresponde a um biótipo craneofacial humano, mas poderia ser considerada como achado sugestivo de características morfoanatômicas típicas de uma espécie de homínido semelhante ao humano.

Originalidade/Valor: A ampliação dos dados biométricos morfoanatômicos da cabeça reforça a hipótese de que morfologicamente seria uma espécie híbrida não humana.

Palavras-chave: Imagem, Cefalometria, Tridáctilo, Bioarqueologia, Relato de Caso Postmortem.

ANÁLISIS TOMOGRÁFICO MORFOMÉTRICO DE LA CABEZA DEL ESPÉCIMEN HUMANOIDE TRIDÁCTILO DE NASCA-PERÚ

RESUMEN

Objetivo: Comunicar el análisis tomográfico y morfométrico de la cabeza del espécimen humanoide tridáctilo de Nasca-Perú.

Método: Investigación de enfoque cualitativo de tipo estudio de caso. Se aplicó el software RadiAnt DICOM Viewer versión 4.2.1 para analizar longitudes, diámetros y volumen en las imágenes tomográficas de la cabeza. El análisis biométrico morfológico aplicó métodos antropométricos mediante algunos puntos craneométricos y ángulos cefalométricos.

Resultados y Discusión: Como resultados se reporta que existen rasgos imagenológicos morfométricos atípicos, extraños y excepcionales en el segmento cefálico del espécimen M01. El análisis cefalométrico basado en el ángulo ANB revelo un patrón esquelético de clase II, y según el análisis de Bjorl-Jarabak posee un perfil facial convexo con crecimiento hipodivergente (Braquifacial). También posee biprotrusión maxilar, protrusión severa de incisivos superiores e inferiores, pérdida de piezas dentarias, presencia de remanentes radiculares, abrasión dental severa, clase canina no valorable, ausencia de tres terceros molares y protrusión ocular. Basados en puntos craneométricos, el ángulo SNA (Sella, Nasion y Punto A) y el ángulo SNB (Sella, Nasion y Punto B) se diagnosticó protrusión maxilar y protrusión mandibular.

Implicaciones de la investigación: Se concluye que la conjugación de rasgos morfoanatômicos poco comunes en el macizo maxilofacial y craneal, no corresponden a un biotipo craneofacial humano, pero podrían ser considerados como hallazgos sugerentes de rasgos morfoanatômicos propios de una especie homínida similar a la humana.

Originalidad/Valor: La ampliación de datos biométricos morfoanatômicos de la cabeza refuerzan la hipótesis de que morfológicamente se trataría de una especie híbrida no humana.



Palabras clave: Imagenología, Cefalometría, Tridáctilo, Bioarqueología, Reporte de Caso Posmortem.

RGSA adota a Licença de Atribuição CC BY do Creative Commons (<https://creativecommons.org/licenses/by/4.0/>).



1 INTRODUCTION

Cephalometric imaging analysis is a morphological and descriptive diagnostic method that offers significant data on the skeletal and dentoalveolar structures (Aguilar-Pérez *et al.* , 2024a), both normal and pathological, of the buccomaxillofacial and cranial architecture ; therefore, it is the responsibility of stomatology to analyze and diagnose alterations of the stomatognathic system (Aguilar-Pérez *et al.* , 2024b; Jiménez *et al.* , 2022; Reis *et al.* , 2020); that is, relating it to the craniometry of the cranial region and the morphometric analysis of the cervical region. Therefore, in this holistic analysis of the buccomaxillofacial and cranial anatomical regions, the Craniocervical Mandibular System (SCCM) must be considered , conceptualized as the functional biomechanical unit, made up of cranial, cervical and maxillomandibular structures , whose axes are represented by the occipito- atloid joint (AOA), temporomandibular joint (TMJ), the hyoid bone system and the dental organs (Reis *et al.* , 2020; Rocabado & Tapia, 1987; Cárdenas *et al.* , 2015). In this same sense, Sandoval *et al.* , points out that the craniofacial and cervical regions constitute adjacent structures, which have a morphological and functional relationship; Likewise, it is specified that both regions are mutually influenced by their musculoskeletal growth patterns (Sandoval *et al.* , 2019). Therefore, this evidence is suggestive of a morpho-functional relationship between the position of the neck and head with the dentofacial morphology and morphometry , which can be studied through a cephalometric imaging analysis.

The present case reported corresponds to a singular dried tridactyl humanoid body that was discovered as a bioarchaeological find , in 2016 in a region between Palpa and Nasca in southern Peru, approximately 400 km south of Lima; which in 2019 was delivered to the "Universidad Nacional San Luis Gonzaga" (UNSLG) in the city of Ica, Peru, and is currently under study, with some preliminary studies. in France, Russia, Mexico, the United States, Switzerland and also in Peru through books (Miles, 2022; Jamin, 2020; Korotkov , 2020; Martínez, 2018) and scientific articles (Hernández- Huaripaucar *et al.* , 2024a; Hernandez-Huaripaucar *et al.* , 2024b) .



postmortem case report corresponds to a humanoid body in a state of desiccation with tridactyly in hands and feet and with an elongated skull called specimen M01, which when analyzed by Carbon-14 showed an age of 1771 ± 30 years, between 240 AD-383 AD” (Hernández- Huaripaucar *The dried body is impregnated with a very fine white powder consisting basically of diatomite, according to spectrometric analysis multielemental carried out in a Peruvian spectrometry laboratory (National University of Engineering, 2022).*

Preliminary studies reported that the head of specimen M01 presents atypical cranial and facial morphological features such as: lack of hair and earlobes, cranial elongation and maxillofacial deformities (Hernández- Huaripaucar *et al ., 2024b*). The cranial elongation does not show superficial traces of cranial compression by external artifacts such as bandages and/or splints, which would have caused the mobilization and deformation of the cranial bones, but would have left physical traces of bone remodeling in these regions (Gálvez-Calla *et al ., 2016*); it also shows an increase of almost 30% of the cranial volume compared to that of humans; therefore, it is necessary to expand and deepen these studies.

Consequently, the purpose of this research is to communicate the tomographic and morphometric analysis of the head of the tridactyl humanoid specimen from Nasca-Peru.

2 METHODOLOGY

Qualitative approach research and type called case study, in the modality of "atypical cases" (Pérez-Luco *et al ., 2017*; Rabinovich , 2014), carried out using the macroscopic analysis method with magnification and tomographic imaging method for the structural analysis of the head of specimen M01. The cephalic analysis applied the technique of morpho-anatomical biometric examination, with craniometric measurements , imaging observations with digital magnification on digital tomographic images.

The image review and measurement process applied the “ RadiAnt DICOM Viewer ” software version 2024.1 that allowed to analyze and measure lengths, diameters, angles and volume in the tomographic images of the head. This software is designed to view medical imaging material in DICOM (Digital Imaging and Communications in Medicine) format; in addition, the software can calibrate and perform three-dimensional volumetric measurements of computed tomographic images (RadiAnt DICOM, 2024).

The biometric imaging analysis included anthropometric methods taking as a reference pattern some craniometric points and cephalometric angles. The craniometric points used were: Sella (S), Nasion (N), Point A (A), Point B (B), Ofrion (Of), Internal occipital protuberance,



Vertex (Vt), Rhinium (Rh), Gnation (Gn), Mentonian (Me) and Gonion (Go). On the other hand, the angular measurements considered were: the SNA angle (Sella, Nasion and point A) and the SNB angle (Sella, Nasion and point B), which are portions of the cephalic sagittal plane between the SN and NA lines or planes, and also between SN and NB, which allowed to identify the maxillary and mandibular protrusion of specimen M01.

The technical measurement and interpretation criteria for the SNA and SNB angles considered a normal value of $82^{\circ} (\pm 2^{\circ})$ for the SNA angle, and $80^{\circ} (\pm 2^{\circ})$ for the SNB angle (Zavaleta, *et al .*, 2024; Tletlephantzin , 2024) . It was determined that these angles indicate the position of the maxilla and mandible with respect to the base of the skull; and that when they are greater or less than normal values, they are interpreted as indicators of protrusion (advancement) or retrusion (retraction) at the maxillary or mandibular level (Zavaleta, *et al .*, 2024; Tletlephantzin , 2024), for example: if the SNA or SNB angle is greater than normal, maxillary or mandibular protrusion is diagnosed respectively; But if the SNA or SNB angle is smaller than normal, it is classified as maxillary or mandibular retrusion.

2.1 CASE PRESENTATION

2.1.1 Cranial examination

analysis using cephalometric parameters based on craniometric points , the SNA angle (Sella, Nasion and Point A) and the SNB angle (Sella, Nasion and Point B) allowed the diagnosis of a double maxillofacial protrusion , that is, simultaneous maxillary protrusion and mandibular protrusion (Figure 1).

Maxillary dentoalveolar protrusion diagnosed cephalometrically by the SNA angle= 108.4° (normal value = $82^{\circ} \pm 2^{\circ}$), means that the maxilla is in an advanced position with respect to the base of the skull. Similarly, the mandibular dentoalveolar protrusion diagnosed cephalometrically by the SNB angle = 90.4° (normal value = $80^{\circ} \pm 2^{\circ}$), indicates that the mandible is in an advanced position with respect to the base of the skull (Figure 2). This double maxillo -mandibular protrusion can be observed with the naked eye in a macroscopic examination and also in a 3D reconstruction tomographic image .



Figure 1

Simultaneous maxillary protrusion and mandibular protrusion (A, B and C)

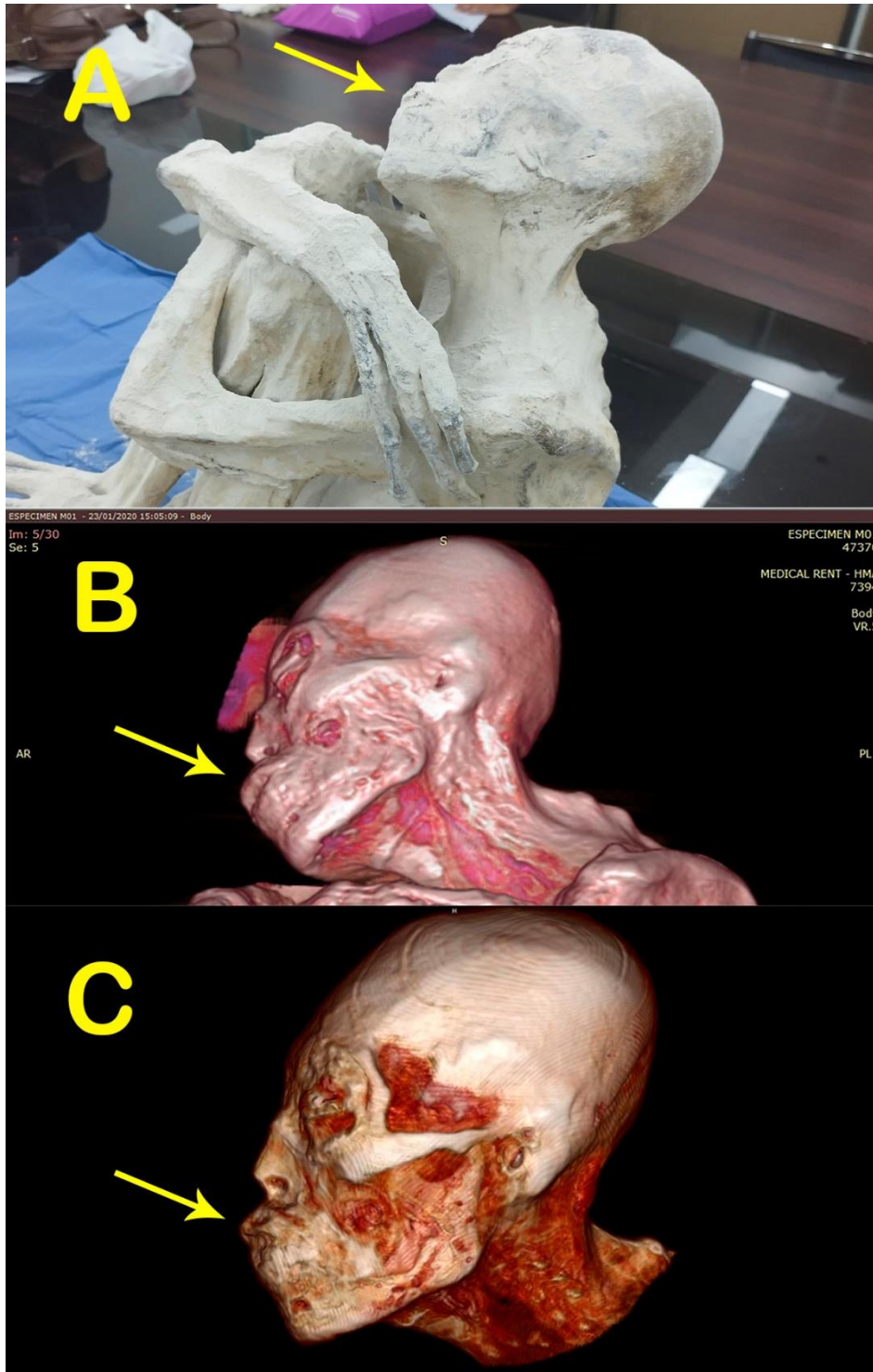
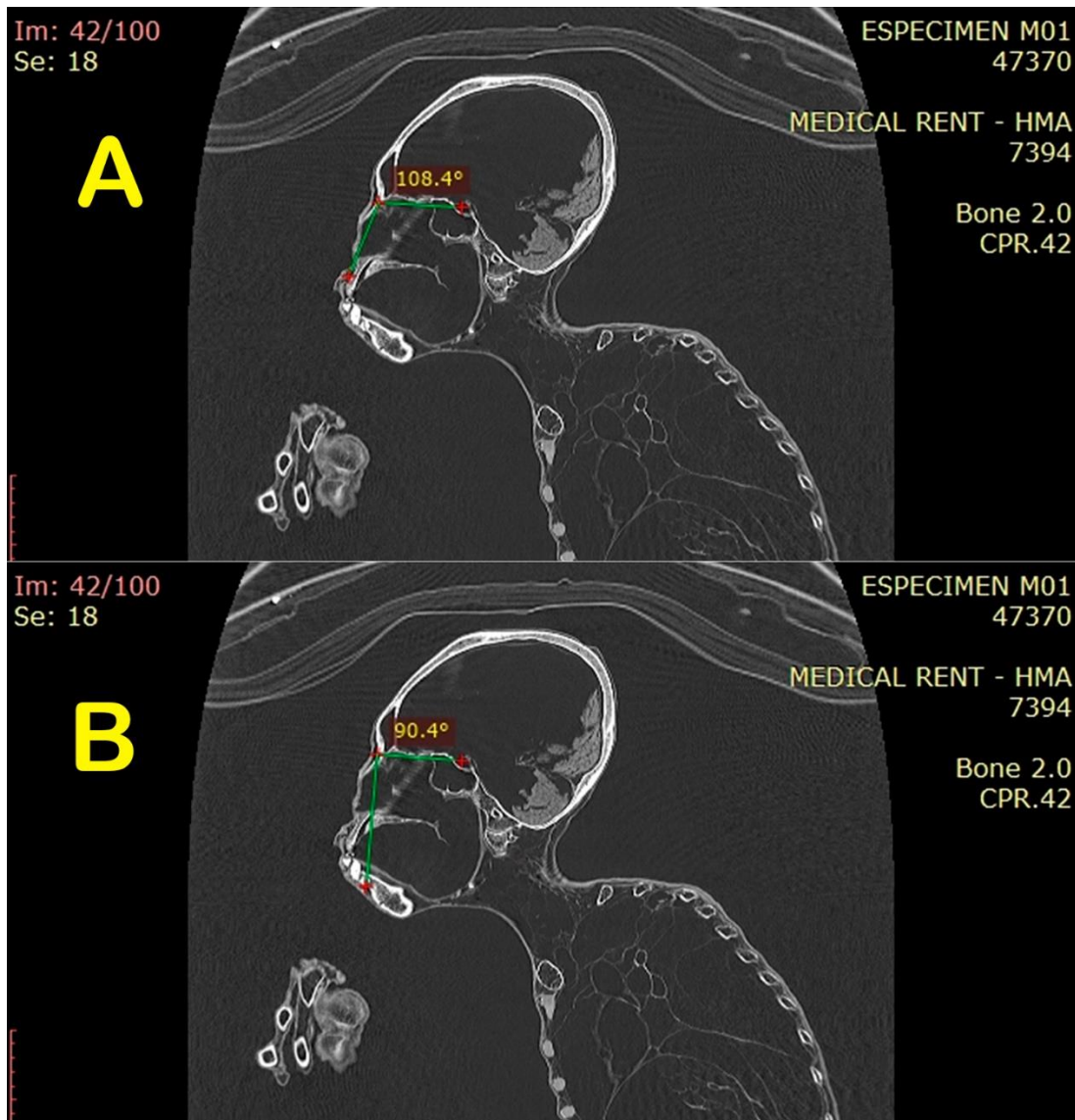




Figure 2

Maxillary and mandibular protrusion diagnosed cephalometrically by the SNA (A) and SNB (B) angles.



vertical and anteroposterior diameters were calculated. of the neurocranium (skull) and the viscerocranium (face) taking as reference some craniometric points . The vertical diameter of the skull was measured from the Sella point to the Vertex , and that of the face from the Gnathion point to the Sella . The anteroposterior diameter of the skull was measured from the Ofrion point to the Internal Occipital Protuberance, while, in the face, it was measured from the Rhinio point to the hyoid bone (figure 3) .

In a frontal tomographic image of the head, the right-left diameters or widths of the skull and face were calculated using cephalometric evaluation , based on bone anatomical landmarks.

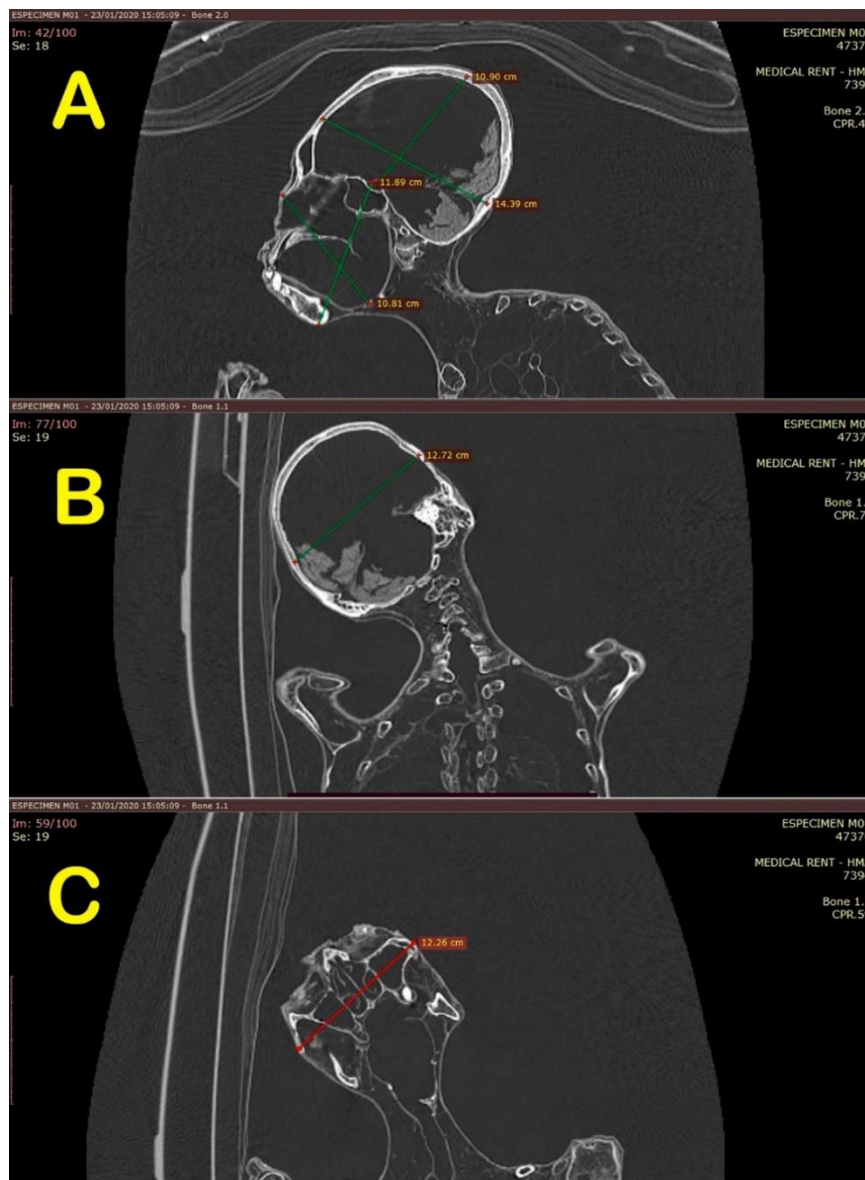


In this way, the width of the skull was calculated using the biparietal diameter (Figure 9), while the width of the face was calculated using the bizygomatic diameter .

According to the digital biometric measurements of the skull: Ofrion- Internal Occipital Protuberance distance = 14.39 cm; Sella- Vertex distance = 10.90 cm; and biparietal distance = 12.72 cm; the cranial volume was calculated, which resulted in 1,995.14 cm³ . Similarly, based on the biometric measurements of the face: Rhinio -Hyoid distance = 10.81 cm; Gnation -Sella distance = 11.89 cm; and bizygomatic distance = 12.26 cm; the volume of the face was calculated, which resulted in 1,575.79 cm³ (Figure 3).

Figure 3

Cephalometric determination of the vertical and transverse diameters of the skull and face



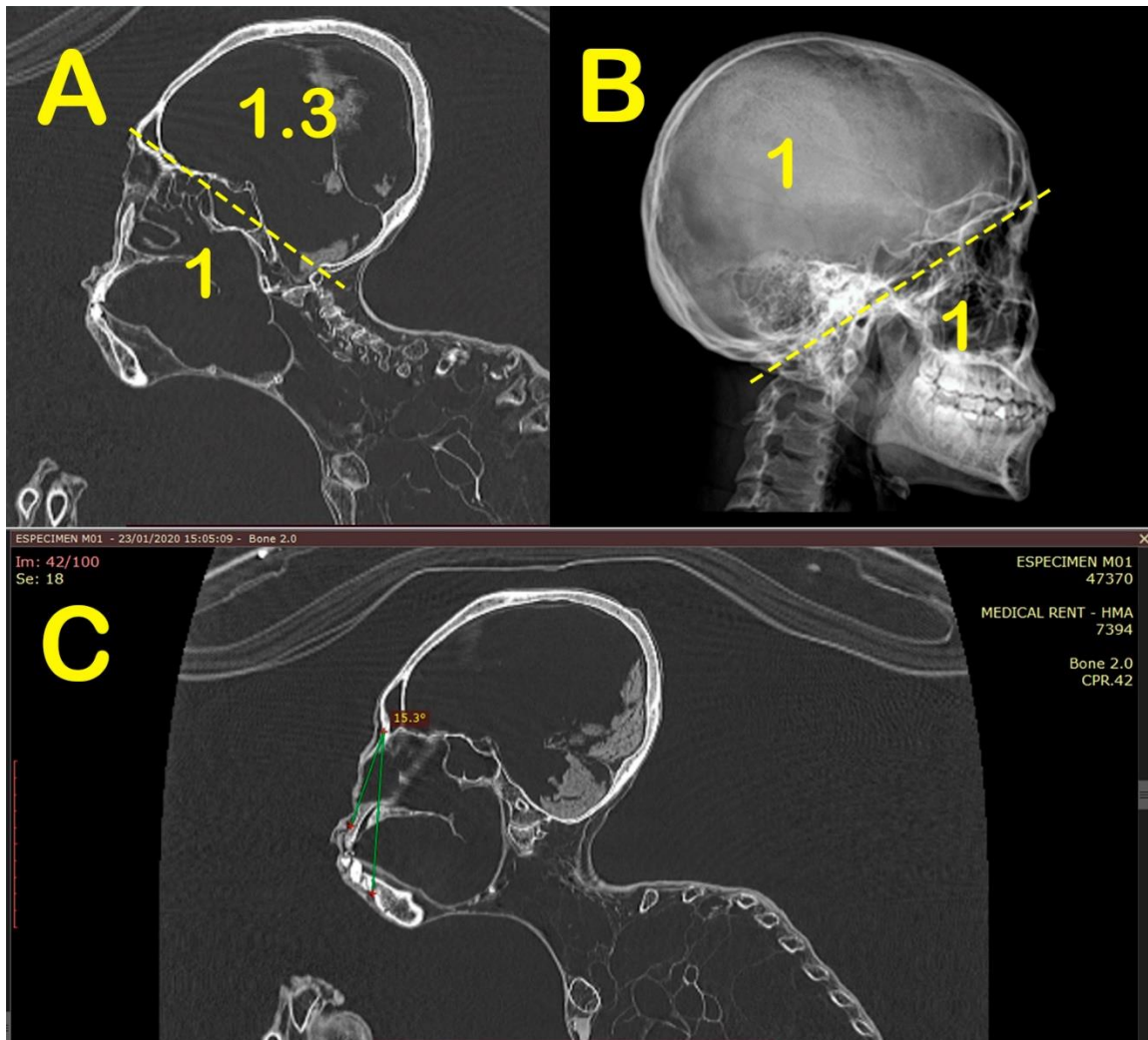


In summary, the cranial volume was $1,995.14 \text{ cm}^3$, and the facial volume (face) was $1,575.79 \text{ cm}^3$ (419.35 cm^3 difference); which means that the M01 specimen has a Skull-Face ratio of 1/1.3 ($1995.14 / 1,575.79 = 1.266$), while in normal humans it is 1/1; these data show that the M01 specimen has about 30% more cranial volume than the average human (figure 4).

The cephalometric analysis also included the diagnosis of the sagittal skeletal pattern that was determined by the ANB angle (Point A, Nasion and Point B) which gave a value of 15.3° , that is, a very wide angle categorized as a class II skeletal pattern (normal pattern = 1° - 4°), which is characterized by excessive growth of the maxilla (Figure 4).

Figure 4

Determination of the proportions of cranial and facial volume (A and B) and the sagittal skeletal pattern using angle ANB (C)



Bjork-Jarabak analysis based on the proportional relationship (ratio) of the posterior and anterior facial heights, a relationship that accounts for the degree of divergence of the



mandibular plane with respect to the Sella- Nasion plane is obtained with the following formula (Ugalde, 2007): Facial Biotype = (Posterior Facial Height/Anterior Facial Height) x 100. The Bjorl-Jarabak Analysis through the posterior facial height (S- Go); and anterior height (N-Me) gave the following findings: and the posterior height was 9.06 mm and the anterior facial height was 11.46 mm ($9.06 / 11.46 = 0.79 \times 100 = 79.057 = 79.06\%$); therefore, the Facial Biotype that would correspond to it would be Hypodivergent (Brachyfacial), since the result obtained is between 64 and 80%; according to this rule, the skull presents a growth direction counterclockwise, also called anterior rotational growth (Cerdeira-Peralta *et al.* , 2019).

Using the method of closure or synostosis of the cranial sutures, also called craniosynostosis (Vallois, 1937; Castillo-Páez *et al.*, 2021), the state of the coronal or frontoparietal suture was analyzed; a state of closure of the distal third (or lateral sector) of the coronal cranial suture was observed, for which an age of between 35-40 years is estimated.

The estimation of sex from cranial features or anatomical observations was based on the criterion that in males the skull is generally larger and more robust, while in females it is generally smaller and more subtle and thin. Sex determination of specimen M01 from the skull was performed considering the glabella, mastoid process, supraorbital arch, frontal protuberances or tuberosities, nuchal crest, zygomatic processes, external occipital protuberance, mental eminence and skull thickness. This identification process was performed by digital visual evaluation of the tomographic images of the skull in the 3D reconstruction window and also in parasagittal and midsagittal images . After evaluating each anatomical feature, a scoring scale was used for each feature, considering a scale of 1 to 5 , where 1 represented a typically female characteristic and 5 a typically male characteristic. The final assessment was then determined by observing whether the sex of the specimen was 100% female. The total sum of the scores was closer to the male or female extreme. The results obtained according to the 9 traits evaluated indicate that specimen M01 would correspond to the male sex.

2.1.2 Extraoral examination

Extraorally , the dried body keeps the neck in slight hyperextension and right lateral inclination, with the head and neck tilted at 38°. Likewise, volumetric alterations of the maxillofacial region are observed, expressed in prominent and advanced maxilla and mandible, labial incompetence, exophthalmic facies, advanced middle third of the face, apparent facial symmetry, upper and lower dental midline apparently coinciding, slightly elongated and oval



face, thick lips; cephalometrically it presents atypical features, with moderate sexual dimorphism and controversial findings (Cerda-Peralta *et al.* , 2019; Carrillo & Camacho, 2020). On the other hand, the temporomandibular joint (TMJ) is without obvious alteration.

This body presents atypical, strange and exceptional morphometric imaging features in the cephalic segment, with a diagnosis based on cephalometric studies of tomographic images, the cephalometric analysis based on the ANB angle reveals a class II skeletal and dental pattern. According to the Bjorl-Jarabak analysis It presents a convex profile, with hypodivergent growth (Brachyfacial) , but, in addition, based on the SNA and SNB angles, a severe maxillary protrusion is observed in the middle third of the face and also, in the lower third of the face, a notable mandibular protrusion, which appears to be a class III malocclusion (Carrillo & Camacho, 2020; Ugalde, 2007).

The nasal region shows a nose of normal appearance and size, but with slight compression. Macroscopic morphological analysis in the orbital region reveals a noticeable protrusion of the eyeballs despite their state of desiccation. Imaging analysis using sagittal tomographic images of the head shows that the desiccated eyeballs are pushed forward in front of the plane of the orbital base, which is why it is classified as severe ocular protrusion.

2.1.3 Intraoral examination

Lack of lip closure, severe protrusion of upper and lower incisors (pieces 1.1, 1.2, 2.2, 3.1, 3.2, 4.1, 4.2), loss of six teeth (pieces 2.8, 3.7, 3.8, 4.6, 4.7, 4.8), presence of four root remnants (pieces 2.1, 2.3, 2.4, 2.5), severe generalized dental abrasion, canine class not assessable, loss of three third molars (2.8, 3.8 and 4.8) with conservation of only the upper right third molar (piece 1.8). At the mandibular level, edentulous areas are observed at the free end bilaterally. (class I according to Kennedy classification); in these edentulous areas, the following can be observed: remaining bone ridges with smooth, regularized surfaces, with no residual traces of interdental bone crests and interradicular crests, nor remains of the vestibular or lingual tables that would be typical of a primitive or rudimentary extraction.

3 DISCUSSION

Considering that the head of specimen M01 shows an increase of almost 30% in cranial volume compared to that of a human and that no obvious signs of artificial cranial deformation expressed in premature obliterations of the cranial sutures are observed; in accordance with



Wolff's law which establishes that bones adapt to the forces exerted on them and remodel themselves by changing shape while the volume remains relatively constant in accordance with mathematical laws (Antón & Weinstein, 1999); it is clear that these findings contribute to the hypothesis that it would be a naturally elongated skull. In this regard, Gálvez *et al.* (2014) reported that bandages and/or splints applied after birth can mobilize the cranial bones, promoting osteoblastic and osteoclastic activities in the sutures, which will produce early obliteration of the compromised sutures and cephalic deformation (Gálvez *et al.*, 2014; Allison *et al.*, 1981). Gálvez *et al.* (2016) also confirmed that, in skulls with artificial deformation, the sutures of the cranial vault are obliterated prematurely between 15 and 21 years of dental age. On the other hand, Cocilovo (1978) reported that linear morphometry studies show that the effects of cranial deformation are manifested mainly in the vault and minimally in the cranial base and facial region; however, M01 shows facial deformation due to a strong maxillary biprotrusion .

According to Cocilovo *et al.* (2011) in the artificial deformation of the head when external compressive forces are applied, the vault should be deformed and compressed, making it logical that the cranial volume is reduced a little or at most remains stable, because forces contrary to normal growth are applied, therefore, based on physical and biological principles of bone architecture (Cocilovo, 1978) it is not consistent to find artificially deformed skulls that have an increase in cranial volume. Therefore, it is likely that the elongation and increase in cranial volume of this atypical skull are really original and natural features of a new hominid species; as reported by Hernández - Huaripaucar *et al.* (2024a, 2024b).

On the other hand, the finding of a Skull-Face volumetric ratio of 1.3/1 in specimen M01, while in normal humans it is 1/1, demonstrates almost 30% more cranial volume (Hernández- Huaripaucar *et al.*, 2024b) and consequently it is deduced that it had approximately 30% more brain mass, including a larger brain volume; therefore it is binding to emphasize that from the point of view of ontogeny and phylogeny, the development and greater relative size of the brain may be associated with higher levels of intelligence in primates and humans, in this line of ideas Delius (2002) and Adolphs (2002), believed that there is an association between brain size and animal body size, that birds and mammals have brains 6-10 times larger than the brains of reptiles with similar body proportions and that brain size has a relative relationship with the intelligence of the animal.

According to Cárdenas *et al.* (2015), there is an interrelation in the orthostatic and morpho-functional balance between the Skull and the cervical region; but despite the fact that in the imaging analysis of M01 at the thoracic and lumbar level vertebral arthropathies were



identified, at the cervical level no morphological, articular or positional alterations are observed that could be interrelated with the atypical craniofacial structural configuration that it has; however, it is known that in the morphological diagnosis of bone, articular and myofunctional discrepancies of the Craniocervical Mandibular System (SCCM), the craniocervical position is a relevant factor to consider. In this same sense, Krishna *et al.* (2023), Salonen *et al.* (1993), and González & Manns (1996) believe that the postures of the head and the cervical spine exert a structural and functional influence on the stomatognathic system; On the other hand, Krishna *et al.* (2023), argue that neck posture has an intense association with the sagittal structure of the face and that it is influenced by various physical or functional factors such as: craniofacial morphology, naso-respiratory or temporomandibular dysfunction. Similarly, González & Manns, claim that the craniocervical postural position has a close link with the mandibular postural position (1996).

Cephalometrically, specimen M01 presents a strong maxillary protrusion determined by the angle SNA= 108.4° (normal value = $82^\circ \pm 2^\circ$); a marked mandibular protrusion diagnosed by the SNB angle = 90.4° (normal value = $80^\circ \pm 2^\circ$) and also presents a sagittal skeletal pattern of class II characterized by excessive growth of the maxilla, which was determined by an oversized ANB angle of 15.3° , compared to the value of 1° to 4° presented by an individual with a normal class I relationship (correct occlusion). These findings may suggest that it would be an alteration of craniofacial growth (Rodríguez & Luna, 2023; Arvidsson *et al.*, 2010), however, in humans according to the biomechanical principles of facial growth of the sagittal skeletal pattern of class II (Arvidsson *et al.*, 2010; Erazo *et al.*, 2016), when this skeletal conformation is developing and consolidating, structural and positional changes occur in parallel in the basilar portion of the occipital bone and in the mandible as components of the Craniocervical Mandibular System (SCCM), which will cause the craniometric point basion, condyle and mandible perform a posterior rotation movement and move backwards producing a mandibular retrusion, therefore this class II skeletal pattern shown by M01 in humans is not compatible with a mandibular protrusion. This evidence suggests that these atypical craniofacial skeletal features of specimen M01 may be normal characteristics of a new species of hominid that probably coexisted with the ancient population of the Nasca culture.

The macroscopic, microscopic and functional anatomy of the human visual apparatus shows that the eyeballs are composed of aqueous humor, vitreous humor, cornea, lens, retina and other structures, which generally have between 80% and 90% water (Hernández, 2019); therefore, in this specimen, the eyeballs, being dehydrated in a state of desiccation, should have been compressed and preserved at the bottom of the orbital cavities; however, the eyeballs of



specimen M01 are protruded in front of the plane of the orbital base, which is considered a severe ocular protrusion. Likewise, the perimeter of the orbital base is larger than normal. These findings would mean that in life this specimen had enormous and bulging eyes.

Oral examination of M01 identified bilateral edentulous areas with very regular smooth bone surfaces, i.e. no residual traces of interdental bone ridges or interradicular ridges were found, nor were any remains of the vestibular or lingual tables, which would be expected as a consequence of accidental tooth loss or non-professional empirical tooth extraction. This is truly a strange finding, even more so considering that the residual bone contained the largest and longest roots of all the teeth, corresponding to the first, second and third molars. Therefore, this controversial but irrefutable evidence suggests that these post-extraction superficial bone topographies of the molar regions are compatible with specialized technical and surgical work.

After describing the proportional characteristics between the skull and face of M01 (1.3/1), it turns out that it is not consistent with the skull/face proportion of the pre-Columbian people of that time, since these ancient Peruvian people had a smaller cranial volume and a larger facial volume, for the following reasons: the skull was not so developed because their brain was not so developed either, given that they belonged to culturally and socially not very developed communities; on the other hand, the facial part of the head, especially the maxillomandibular massif, was very well developed due to the demanding mastication and multifunctionality they had, because their alveolar-dental system (including the bone base) was not only part of the masticatory system, but also part of their defense system and their daily work tools. Consequently, these arguments and the finding of a larger cranial volume in M01 in ancient times, show that it does not correspond to the cranial biotype of the ancient Nasca people ; which contributes further to the hypothesis that specimen M01 would biologically be another hominid species similar to *Homo sapiens*.

4 CONCLUSIONS

Cephalometric analysis allowed to diagnose the sagittal skeletal pattern of M01, through the ANB angle, which resulted in a class II skeletal pattern. The Bjorl-Jarabak Analysis through the posterior and anterior facial height resulted in the Hypodivergent Facial Biotype (Brachyfacial).

Using the method of closing cranial sutures or craniosynostosis, the age of M01 was estimated to be between 35-40 years. Sex estimation based on the assessment of nine cranial anatomical features or observations indicated that specimen M01 was male. Extraoral



examination of M01 identified a slightly hyperextended neck with a 38° right lateral inclination, volumetric alterations in the maxillofacial region, expressed in prominent and forward maxilla and mandible, lip incompetence, exophthalmic facies, and other atypical facial features.

Macroscopic morphological analysis in the orbital region reveals a severe protrusion of the eyeballs and tomographic imaging analysis shows a strong forward posture of the eyeballs with respect to the plane of the orbital base.

Intraoral examination of M01 revealed a lack of lip closure, severe protrusion of upper and lower incisors, loss of six teeth, presence of four root remnants, severe generalized dental abrasion, and absence of three third molars. At the mandibular level, bilateral edentulous areas were observed at the free end (Kennedy class I); in said edentulous areas, the following were observed: residual bone ridges with very regular smooth surfaces, not compatible with a supposedly primitive or rudimentary extraction.

The combination of uncommon morphoanatomical features in the maxillofacial massif, orbital region and cranial vault expressed in maxillary biprotrusion , ocular biprotrusion and cranial elongation do not correspond to the craniofacial biotype of an average human, but can be considered as suggestive findings of morphoanatomical features typical of a hominid species similar to humans that could correspond to an evolutionary line parallel to humans or to a species exogenous to the region where it was found.

Specimen M01 in the cephalic examination under cephalometric criteria based on the SNA and SNB angles presented a facial deformation expressed in a double maxillo -facial protrusion, also, the increase in the Skull- Face volumetric ratio (1.3/1), demonstrated a greater cranial volume and consequently it is deduced that in life it had approximately 30% more brain mass including the brain.

REFERENCIAS

- Adolphs, R. (Ed.). (2002). *Emoción y conocimiento: la evolución del cerebro y la inteligencia*. Barcelona: Tusquets Ed., 15-65.
- Aguilar-Lugo H. A., Zalnieriunas-Montero A., Terán-de Orozco B., Falótico-de Farías G. J., & Dommar-Pérez B. (2024). Recursos imagenológicos para el diagnóstico y seguimiento de las alteraciones del paciente con disfunción del sistema cráneo-cérvico mandibular. *Reporte Imagenológico Dentomaxilofacial*, 3(1), e2024030102. <https://doi.org/10.60094/RID.20240301-32>
- Aguilar-Pérez F. J., Bataller-Méndez E. B., Colomé-Ruiz G. E., Chuc-Gamboa M. G., Aguilar-Pérez D. A., & Herrera-Atoche J. R. (2024). Agreement Between Two Cephalometric



- Analyses of Facial Growth Direction and Biotype. *Odvotos-International Journal of Dental Sciences*, 26(2), 124-133. <https://doi.org/10.15517/ijds.2024.58334>
- Allison M. J., Gerszten E., Munizaga J., Santoro C., & Focacci G. (1981). La práctica de la deformación craneana entre los pueblos andinos precolombinos. *Chungará*, 7(81), 238-260. Departamento de Antropología, Universidad del Norte, Arica. Chile. <https://www.jstor.org/stable/27801727>
- Antón, S. C., & Weinstein, K. J. (1999). Artificial Cranial Deformation and the Radiographic Appearance of Wormian Bones. *American Journal of Physical Anthropology*, 109(2), 221-232.
- Arvidsson L. Z., Fjeld M. G., Smith H. J., Flatø B., Ogaard B., & Larheim T. A. (2010). Craniofacial growth disturbance is related to temporomandibular joint abnormality in patients with juvenile idiopathic arthritis, but normal facial profile was also found at the 27-year follow-up. *Scandinavian Journal of Rheumatology*, 39(5), 373-9. <https://doi.org/10.3109/03009741003685624>
- Cárdenas J. M., Flores J. C., Gutiérrez F. G., Cárdenas G., Sánchez W., & Guerrero A. L. (2015). Estudio morfométrico de la posición cráneo-cervical en pacientes con clases esqueléticas II y III. *International Journal of Morphology*, 33(2), 415-19. <https://dx.doi.org/10.4067/S0717-95022015000200001>
- Carrillo R. A. J., & Camacho M. E. K. (2020). Tratamiento ortodóntico-quirúrgico de maloclusión clase III con apiñamiento severo: reporte de un caso. *Revista Mexicana de Ortodoncia*, 8(1), 41-49. <https://www.medigraphic.com/cgi-bin/new/resumen.cgi?IDARTICULO=102851>
- Castillo-Páez, J. A., Villasmil-Suárez, L. G., & Guada-Melet, N. V. (2021). Rasgos antropométricos craneofaciales de interés odontológico forense en la estimación de sexo, grupo étnico y edad. Revisión de la literatura. *Revista científica odontológica*, 9(1), e047. <https://doi.org/10.21142/2523-2754-0901-2021-047>
- Cerda-Peralta, B., Schulz-Rosales, R., López-Garrido, J., & Romo-Ormazabal, F. (2019). Parámetros cefalométricos para determinar biotipo facial en adultos chilenos. *Revista clínica de periodoncia, implantología y rehabilitación oral*, 12(1), 8-11. <http://dx.doi.org/10.4067/S0719-01072019000100008>
- Cocilovo J. A. (1978). Estudo de dois fatores que influenciam a morfologia craniana em uma coleção patagônica: sexo e deformação artificial. *Arquivo de anatomia e antropologia*, 3(3), 113-141.
- Cocilovo J. A., Varela H. H., & O'Brien T. G. (2011). Effects of artificial deformation on cranial morphogenesis in the south central Andes. *International Journal of Osteoarchaeology*, 21(3), 300-312. <https://doi.org/10.1002/oa.1141>
- Delius, J. (2002). Inteligencias y cerebros: un enfoque comparativo y evolutivo. *Konstanzer Online-Publikations-System (KOPS)*. <http://nbn-resolving.de/urn:nbn:de:bsz:352-206821>
- Erazo C., Ríos M., Troncoso E., & Quezada G. (2016). Distracción ósea del tercio medio facial en malformaciones Cráneo-Maxilofaciales. *Revista Médica Clínica Las Condes*, 27(1), 5-13. <https://doi.org/10.1016/j.rmclc.2016.01.002>



- Gálvez, C. L., Maita V. L., Guillén B. C., & Menéndez M. L. (2014). Implicancias culturales en la morfología craneana de grupos étnicos pre-colombinos peruanos. *Odontología sanmarquina*, 17(1), 20-25. <https://doi.org/10.15381/os.v17i1.9760>
- Gálvez-Calla L. H., Suarez-Canlla C. A., Maita L., Munive A., & Ramos V. (2016). Estimación etárea del comportamiento sutural en cráneos peruanos precolombinos con deformación cefálica artificial. *Odontología Sanmarquina*, 19(2), 29-34. <https://doi.org/10.15381/os.v19i2.12915>
- González, H. E., & Manns, A. (1996). Forward Head Posture: Its Structural and Functional Influence on the Stomatognathic System, a Conceptual Study. *Cranio*, 14(1), 71–80. <https://doi.org/10.1080/08869634.1996.11745952>
- Hernández, S. E. (2019). Conceptos anatomo-histológicos y funcionales del aparato visual. En: Hernández, S. (Ed.), *Enfermedades oculares frecuentes. Manual de consulta-atlas para el médico general* (pp. 1-11). Jaypee-Highlights Medical Publishers, Inc. https://www.researchgate.net/publication/372764002_ENFERMEDADES_OCULARES_FRECUENTES_Manual_de_consulta-atlas_para_el_medico_general
- Hernández-Huaripaucar, E., Becerra-Canales, B., & Ybaseta-Medina, J. Hallazgos morfoanatómicos de tridactilia en espécimen humanoide de Nasca-Perú. (2024). *Revista Médica Panacea*, 13(1), 2-5. <https://doi.org/10.35563/rmp.v13i1.563>
- Hernández-Huaripaucar, E., Zúñiga-Avilés, R., Becerra-Canales, B., Suarez-Canlla, C., Mendoza-Vizarreta, D., & Zúñiga-Almora, I. (2024). Biometric Morpho-Anatomical Characterization and dating of the antiquity of a Tridactyl Humanoid Specimen: Regarding the case of Nasca-Peru. *Revista de Gestão Social e Ambiental*, 18(5), e06916. <https://doi.org/10.24857/rgsa.v18n5-137>
- Jamin T. (2020). *Les momies non humaines de Nazca. Un evenement historique*. Paris: Les Editions Atlantes.
- Jiménez Y., Machado M., Véliz O. L., Barreto E., & Jiménez L. (2022). Enfoque integral en el diagnóstico del patrón esquelético maxilomandibular, la postura corporal y cráneo-cervical. *Revista Cubana de Estomatología*, 59(1), e3545. <https://www.medigraphic.com/cgi-bin/new/resumen.cgi?IDARTICULO=114109>
- Korotkov K. (2020). *The mysterious mummies of Nazca: eyewitness testimony*. Editorial Independently published.
- Krishna S. S., Shashikumar B., & Naik R.D. (2023). Evaluation and comparison of cervical spine posture in Class II division I patients treated with twin block appliances, forsus appliances, and bilateral sagittal split osteotomy: A cephalometric study. *Contemporary clinical dentistry*, 14(2), 157-65. https://doi.org/10.4103/ccd.ccd_459_22
- Martínez, C. I. (2018). *ADN no coincidente. Tridáctilos desecados de Nazca y palpa*. Suiza: ONG SCRIT Editorial.
- Miles C. (2022). *The miles paper*. Utah, USA: The Miles paper.com Editorial.
- Pérez-Luco, A.R., Lagos, L., Mardones, R., & Sáez, F. (2017). Taxonomía de diseños y muestreo en investigación cualitativa. Un intento de síntesis entre las aproximaciones



- teórica y emergente. *Ámbitos. Revista Internacional de Comunicación*, (39);13. <https://idus.us.es/handle/11441/68886>
- Rabinovich, D. L. (2014). El rol de los casos atípicos con el trasfondo de las cuestiones sobre predicción y explicación en ciencias. Revisión de dos ejemplos en neurociencias cognitivas. In *IX Encuentro AFHIC/XXV Jornadas Epistemología e Historia de las Ciencias*. <http://conferencias.unc.edu.ar/index.php/afjor/AfhicIX/paper/view/2441>
- RadiAnt DICOM (2024). *RadiAnt DICOM Viewer User manual*. <https://www.radiantviewer.com/>
- Reis C., Fernandes C., Gribel, S., Frazão B., Cherubini G., Menezes C. & Custodio G. (2020). Mandibular ramus height and condyle distance asymmetries in individuals with different facial growth patterns: a cone-beam computed tomography study. *Surgical and Radiologic Anatomy. Surgical and Radiologic Anatomy*, 43, 267-274. <https://doi.org/10.1007/s00276-020-02577-6>
- Rocabado M., & Tapia V. (1987). Radiographic study of the craniocervical relation in patients under orthodontic treatment and the incidence of related symptoms. *Cranio*, 5(1), 36-42. <https://doi.org/10.1080/08869634.1987.11678172>
- Rodríguez S. T., & Luna A. P. (2023). Cambios cefalométricos en pacientes con prognatismo y pseudo prognatismo mandibular pre y postquirúrgicos. *Revista Científica Especialidades Odontológicas UG*, 6(1), 56-65. <https://doi.org/10.53591/eoug.v6i1.1634>
- Salonen, M. A. M., Raustia, A. M., Huggare, J., & Smith, S. D. (1993). Head and Cervical Spine Postures in Complete Denture Wearers, *Cranio*, 11(1), 30-35.
- Sandoval, C., Díaz A., & Manríquez G. (2019). Relationship between craniocervical posture and skeletal class: A statistical multivariate approach for studying Class II and Class III malocclusions. *Cranio*, 39(2), 1-8. <https://doi.org/10.1080/08869634.2019.1603795>
- Tletlepanzin S. (2024). Nuevos métodos de identificación odontológica forense. *Revista Criminología y Ciencias Forenses: Ciencia, Justicia y Sociedad*, 3(5), 23-33. <https://cf-cjs.uicui.edu.mx/ojs/index.php/CJS/article/view/54>
- Ugalde M. F. (2007). Clasificación de la maloclusión en los planos anteroposterior, vertical y transversal. *Revista de la Asociación Dental Mexicana ADM*, 64(3), 97-109. <https://www.medigraphic.com/cgi-bin/new/resumen.cgi?IDARTICULO=12242>
- Universidad Nacional de Ingeniería UNI. (2022). *Informe técnico de análisis espectral multielemental*. Laboratorio de Espectrometría de la Facultad de Ingeniería Geológica, Minera y Metalúrgica de la UNI.
- Vallois H. V. (1937). La durée de la vie chez l'homme fossile. *Comptes Rendus des Academie des Sciences*, 204, 60-62.
- Zavaleta, C. S., Barradas, J. R., Martínez, A., & Muñoz, V. H. (2024). Correlación entre el método de trazado cefalométrico manual y el programa de trazado cefalométrico nemostudio 2020. *LATAM Revista Latinoamericana de Ciencias Sociales y Humanidades*, 5(1), 3183-3202. <https://doi.org/10.56712/latam.v5i1.1825>